

Huge (Voluminous) Femoral hernia in a male (Case Report)

Karim AL-Araji

College of Medicine, University of Babylon

ARTICLE INFO

Submission date: 3 / 5 / 2018

Acceptance date: 12 / 6 / 2019

Publication date: 31 / 12 / 2019

Abstract

Femoral hernia is usually of a small size. It is more common in females than males and presents in a strangulation. It is considered a huge (Voluminous) if it exceeds a volume of a fist. Herewith, A 54-year-old thin man presents with an irreducible but non-strangulated huge right femoral hernia. Diagnosis was confirmed by history and physical examination. Preoperative laboratory and chest x-ray were normal. Open mesh repair was done with uneventful postoperative course. The patient was well after 18 months of operation without recurrence.

Keywords : Huge femoral Hernia, Male

Introduction

Femoral hernia is relatively rare, it forms about 5% of all abdominal hernias (1, 2), 2-4% of all groin hernias, more common in females than males with in 2:1 ratio M: F ration. (3). Usually it is of a small size and presents in a strangulation in 40% of cases (4, 5, 6, 3). The diagnosis is usually established by history and physical examination, rarely other investigations may be needed when the diagnosis is not clear (7, 6, 8) If it exceeds the volume of a fist, it is considered a huge (Voluminous) (9,10, 11). This presents therapeutic difficulties owing to, mainly, respiratory compromise if the contents are reduced to the abdomen due to loss of domain. MEDLINE search was done for huge femoral hernia in males which showed paucity of information in this field.

This case is recorded because it presented in a thin male, uncomplicated and in a huge size.

Case presentation

A 54-year-old thin man, primary school teacher, walks about 7 Km daily on feet, who had no past medical history of any medical illness. He presents with a large right groin swelling causing embarrassment to him for the last five years. O /E the swelling occupies the medial side of the thigh displacing the scrotum and the penis to the left side, the skin colour was normal, cough impulse was present. It is irreducible but soft with normal temperature, not tender, its neck is below and lateral to the pubic tubercle and it was impossible to get above it. Bowel sounds on the swelling were normal. The abdomen was scaphoid, not distended, not tender and bowel sounds were normal.

Digital rectal examination was normal. The left groin was normal. Diagnosis of very big right femoral hernia was ascertained on the basis of history and physical examination (Fig.1)

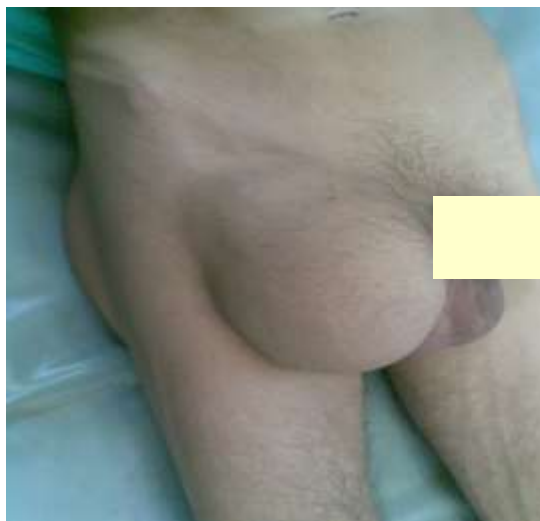

Fig 1 : Huge right femoral hernia

Preoperative basic laboratory including complete blood count, urinalysis, renal function test, fasting blood sugar, ECG, chest x-ray were all within normal. Informed consent was ascertained and elective open operative mesh repair was planned. The patient was explored under general anesthesia through

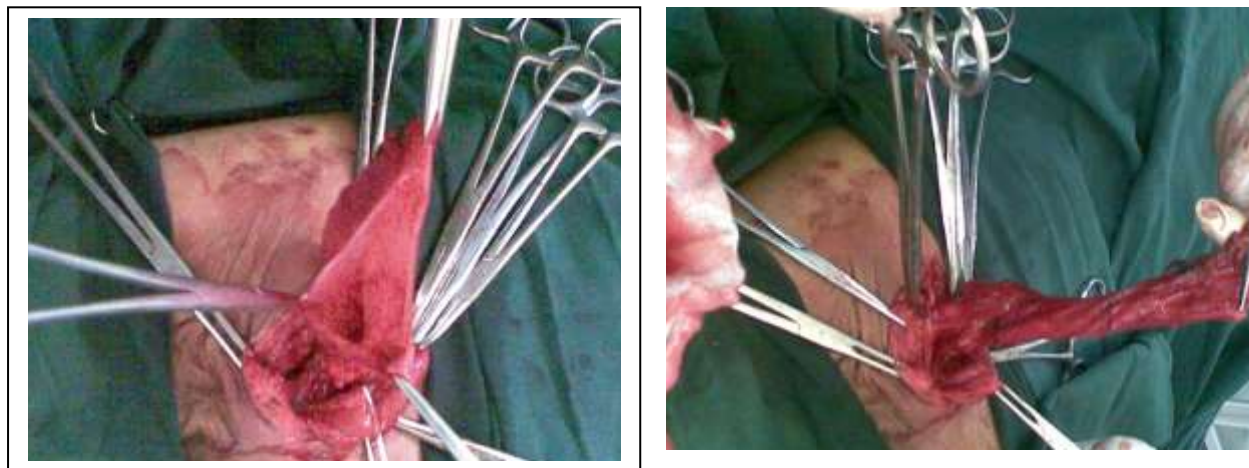


Fig 2: The contents were reduced and the big hernia sac is visualized

an incision above the inguinal ligament. There was a big femoral hernia , the inguinal ligament is attenuated. The sac was impossible to be reduced, femoral ring was enlarged, sac delivered above inguinal ligament, opened and it revealed a viable small bowel which was reduced. Herniotomy with high ligation of the sac was done **Fig. 2**. A polypropylene mesh 15 X 15cm was laid down to occlude the femoral ring and cover the posterior wall of the inguinal canal. The patient run a smooth uneventful postoperative course and was discharged from the hospital on the first postoperative

day. Stitches were removed on 7th postoperative day. The patient was well eighteen month after without recurrence.

Discussion

Femoral hernia usually has a small size, occurs in multiparous obese female due to weakness of abdominal muscles (1,4). This patient is a thin man, has a huge femoral hernia. This means that femoral hernia can occur in a thin male patient probably due to deficiency of fat which normally fills the femoral canal where this hernia occurs.

Sixty percent of patients present as an emergency in strangulation(3, 4). This patient has an irreducible but not obstructed hernia and managed electively. Life style of this patient with a lot of waking may have lead to a gradual reduction in the amount of fatty tissue that occlude the femoral canal with a free herniation of bowel without being obstructed.

Femoral hernia can be repaired either by tissue or mesh whether through open or laparoscopic approach depending on the size of the hernia, personal preference and available facility (2, 12). Most of the literature advocate plugging of the femoral canal with mesh (4, 13, 8,14, 15, 16). This hernia is repaired with preperitoneal application of mesh without plugging of femoral canal which covers the femoral opening and strengthens the posterior wall of inguinal canal.

Conclusion

Although femoral hernia is common in females, rare in males and usually presents in a small size and in a strangulation, this case report showed that it can occur in a thin male without strangulation.

Conflict of Interests.

There are non-conflicts of interest .

References:

1. Olalekan Olasehinde, Amarachukwu C Etonyeaku, Elugwaraonu A Agbakwuru, Ademola O Talabi, Funmilola O Wuraola, and Adebayo G Tanimola. Pattern of abdominal wall herniae in females: a retrospective analysis. *Afr Health Sci.* 2016 Mar; 16(1): 250–254.
2. Nobutoshi Soeta, Takuro Saito, Tetsutaro Nemoto, Ikuro Oshibe, and Mitsukazu Gotoh : Laparoscopic repair of irreducible femoral hernia containing the fallopian tube alone: a case report. *Surg Case Rep.* 2016 Dec; 2: 57. Published online 2016 Jun 6. Doi: 10.1186/s40792-016-0185-y
3. Sapna Purushotham, Srinivas B. Kulkarni, Kshirsagar, Mudasser Rehan4, Manjunathv : Strangulated femoral hernia in a male patient – diagnostic dilemma ; Case report; *Journal of Evolution of Medical and Dental Sciences/ Volume 3/ Issue 05/February 03, 2014: 1160- 1162 ;DOI: 10.14260/jemds/2014/1961*
4. Hachisuka T. Femoral hernia repair. *Surg Clin North Am.*2003; Oct;83(5):1189-205.
5. Ram BR· Goud VS· Kumar DR· Reddy BK. Strangulated Groin Hernia Repair: A New Approach for All. *J Clin Diagn Res.* 2016; Apr;10(4).

6. Vivek Ambedkar, Abhilash Singh, Jayanta Bain, and Lal Mani Singh: A rare case of femoral herniation of female internal genitalia
J Nat Sci Biol Med. 2015 Jul-Dec; 6(2): 454-456. Doi: 10.4103/0976-9668.160038
7. Gupta H, Subedi N, Robinson P. Effectiveness of Sonography in Detecting Clinically Occult Femoral Hernias. J Ultrasound Med. 2016 Jun 22. Pii: 15.09045.
8. Rosenberg J, Bisgaard T, Kehlet H, Wara P, Asmussen T, Juul P, Strand L, Andersen FH, Bay-Nielsen M; Danish Hernia Database. Danish Hernia Database recommendations for the management of inguinal and femoral hernia in adults. Danish Med Bull. 2011 Feb;58(2):C4243.
9. Ursula Dahlstrand, Gabriel Sandblom, Staffan Wollert, Ulf Gunnarsson. Limited Potential for Prevention of Emergency Surgery for Femoral Hernia. World Journal of Surgery August 2014, Volume 38, Issue 8, pp 1931-1936
10. Paweł Osemek, Krzysztof Paśnik, Piotr Trojanowski: Huge, irreducible femoral hernia interpreted as a preperitoneal lipoma in radiological findings; Videosurgery and other miniinvasive techniques 2010; 5 (1): 35-37
DOI: 10.5114/wiitm.2010.13605.
11. René E. Stoppa : The treatment of complicated groin and incisional hernias ; World Journal of Surgery; September 1989, Volume 13, Issue 5, pp 545-554.
12. Yinghan Song, phd nanqing Lu, MD Dongyang Ma, MD Yong Wang, phd Xiaoting Wu, phd, Wenzhang Lei, MD : Long-term results of femoral hernia repair with ULTRAPRO Plug. Hernia Center of Department of Gastrointestinal Surgery, West China Hospital of Sichuan University, Chengdu, China
DOI: <http://dx.doi.org/10.1016/j.jss.2014.10.058>
13. Pangen A, Shakya VC, Shrestha AR, Pandit R, Byanjankar B, Rai S : Femoral hernia: reappraisal of low repair with the conical mesh plug. Hernia. 2016 May
14. Chen J, Lv Y, Shen Y, Liu S, Wang M. A prospective comparison of preperitoneal tension-free open herniorrhaphy with mesh plug herniorrhaphy for the treatment of femoral hernias. Surgery. 2010 Nov;148(5):976-81. Doi: 10.1016/j.surg.2010.02.006. Epub 2010 Mar 31.
15. Babar M, Myers E, Matingal J, Hurley MJ. The modified Nyhus-Condon femoral hernia repair. Hernia. 2010 Jun;14(3):271-5. Doi: 10.1007/s10029-009-0606-y. Epub 2010 Jan 5.
16. Paolo G Sorelli, Nabil S El-Masry² and William V Garrett¹: Open femoral hernia repair: one skin incision for all; *World Journal of Emergency Surgery* 2009, 4:44 doi:10.1186/1749-7922-4-44.

الخلاصة

من المعروف ان الفتق الفخذي اكثر شيوعا في المرضى الأناث منه في الذكور و في اكثر الأحيان يكون الفتق صغير الحجم و يشخص بعد حصول المضاعفات و هي اختناق الفتق. هذه الحالة المرضية التي تم تسجيلها تشمل تشخيصا لفتق فخذي كبير جدا غير مختنق لمرضى ذكر عمره 54 سنة بالأعتماد على الفحص السريري. و بعد اجراء التحاليل الطبية اللازمة و اشعة الصدر تم اجراء العملية اللازمة لتصليح الفتق باستعمال الشبكة بدون مضاعفات وهذه تعتبر من الحالات النادرة. وتم متابعة المريض لمدة 18 شهرا بعد العملية دون رجوع الفتق.

الكلمات الدالة: فتق فخذي كبير, مريض ذكر.